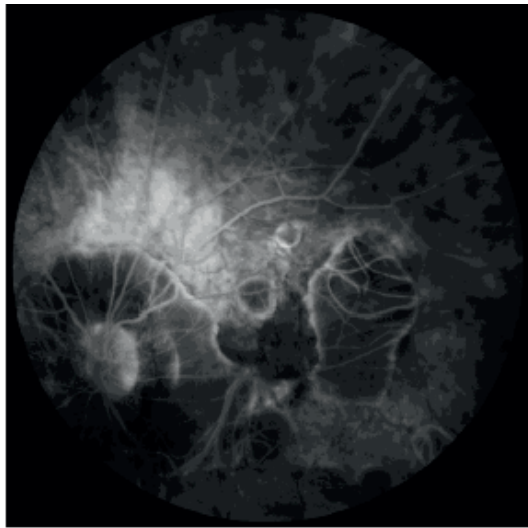


Angio patient case: Myopic CNV



Myopic CNV

Physician: Carl Glittenberg MD, Karl Landsteiner Institute for Retinal Research and Imaging, Vienna, Austria

Patient history:

Gender: Female

Age: 72

Diagnosis: Myopic CNV on the left eye

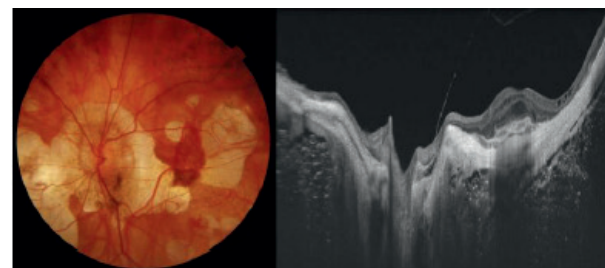
Treatment: 5 intravitreal injections of anti-VEGF on the left eye

Examination techniques and results:

A high-definition swept source OCT B scan, a full color fundus photograph, a fluorescein angiography, and a swept source OCT angiography (SS OCT Angio™) were performed. The examinations were collected on a Topcon DRI OCT Triton™ Plus swept source OCT system. The fundus photograph shows a highly myopic fundus with peripapillary atrophy and an older myopic neovascular lesion with a fresh component on the inferior margin. The B scan shows a myopic fundus, retinoschisis, and intraretinal fluid over the fresh part of the lesion. The fluorescein angiography (top left image) shows leakage in the fresh inferior component. The SS OCT Angio™ (middle and bottom left images) clearly shows vascular proliferation in the area of leakage. OCT Angio images were post processed by Carl Glittenberg MD.

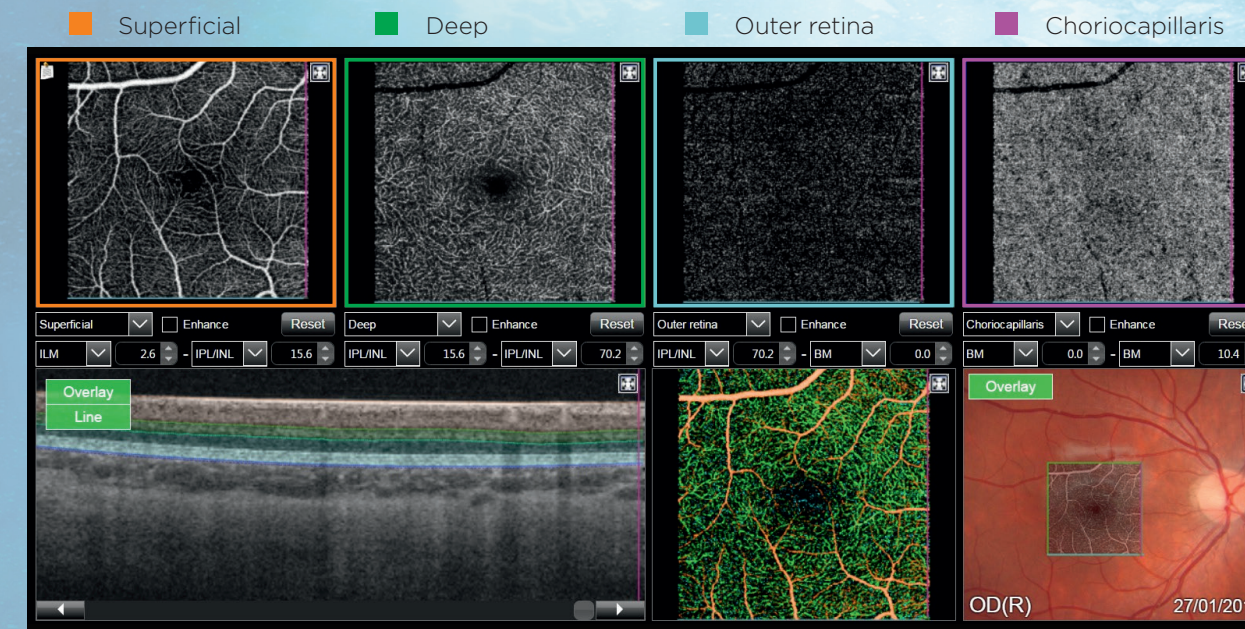
Clinical relevance:

The ability to perform SS OCT Angio™ on highly myopic patients is of great importance for early detection of myopic CNV.



Multimodal viewing & reporting

Angiography images, high-quality B scans and fundus photography can all be viewed on a single screen using IMAGEnet 6, so the area of interest can be assessed using multiple image modalities. Selected layers can easily be customized to enhance the clarity of specific pathological features. *IMAGEnet 6 software is optional

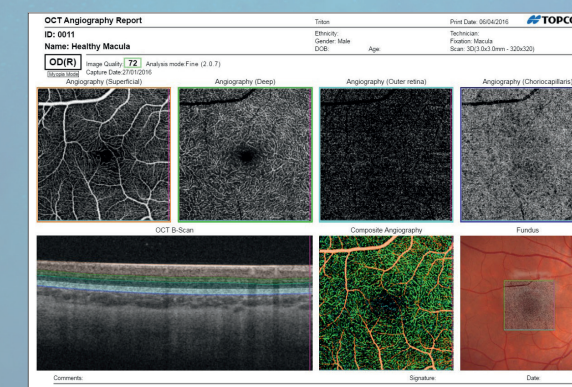


High-quality B scan identified with blue line on each image. The area is identified by the frame color.

Color composite map

Color/FA/FAF/Red-free/ICG can be used
*The FA & ICG are only available if they are imported

Sample report



DRI OCT Triton: SS OCT / Anterior SS OCT (Option) / Color / OCT Angiography (Option)
DRI OCT Triton plus: SS OCT / Anterior SS OCT (Option) / Color / FA / FAF / OCT Angiography (Option)

* Not available for sale in the United States.
* Not available in all countries, please check with your distributor for availability in your country.
* Subject to change in design and/or specifications without advanced notice.
IMPORTANT In order to obtain the best results with this instrument, please be sure to review all user instructions prior to operation.



Topcon Europe Medical B.V.
Essebaan 11, 2908 LJ Capelle a/d IJssel, P.O. Box 145,
2900 AC Capelle a/d IJssel, The Netherlands
Phone: +31-(0)10-4585077; Fax: +31-(0)10-4585045
E-mail: medical@topcon.eu; www.topcon-medical.eu

Topcon España S.A.
HEAD OFFICE: Frederic Mompou, 4,
08960 Sant Just Desvern, Barcelona, Spain
Phone: +34-93-4734057; Fax: +34-93-4733932
E-mail: medical@topcon.es; www.topcon.es

Topcon Deutschland GmbH
Hanns-Martin-Schleyer Strasse 41,
D-47877 Willich, Germany
Phone: (+49) 2154-885-0; Fax: (+49) 2154-885-177
E-mail: info@topcon-medical.de; www.topcon-medical.de

Topcon Ireland
Unit 276, Blanchardstown, Corporate Park 2
Ballycoolin, Dublin 15, Ireland
Phone: +353-18975900; Fax: +353-182933915
E-mail: medical@topcon.ie; www.topcon.ie

Topcon Danmark
Præstemarksvej 25, 4000 Roskilde, Denmark
Phone: +45-46-327500; Fax: +45-46-327555
E-mail: info@topcon.dk
www.topcon.dk

Topcon Italy
Viale dell'Industria 60,
20037 Paderno Dugnano, (MI) Italy
Phone: +39-02-9186671; Fax: +39-02-91081091
E-mail: info@topcon.it; www.topcon.it

Topcon Polska Sp. z o.o.
ul. Warszawska 23, 42-470 Siewierz, Poland
Phone: +48-(0)32-670-50-45; Fax: +48-(0)32-671-34-05
www.topcon-polska.pl

Topcon Scandinavia A.B.
Neogatan 2, P.O. Box 25, 43161 Mölndal, Sweden
Phone: +46-(0)31-7109200; Fax: +46-(0)31-7109249
E-mail: medical@topcon.se; www.topcon.se

Topcon France
BAT A1, 3 route de la révolte, 93206 Saint Denis Cedex
Phone: +33-(0)1-49212323; Fax: +33-(0)1-49212324
E-mail: topcon@topcon.fr; www.topcon-medical.fr

Topcon (Great Britain) Ltd.
Topcon House, Kennet Side, Bone Lane, Newbury
Berkshire RG14 5PX, United Kingdom
Phone: +44-(0)1635-551120; Fax: +44-(0)1635-551170
E-mail: medical@topcon.co.uk; www.topcon.co.uk

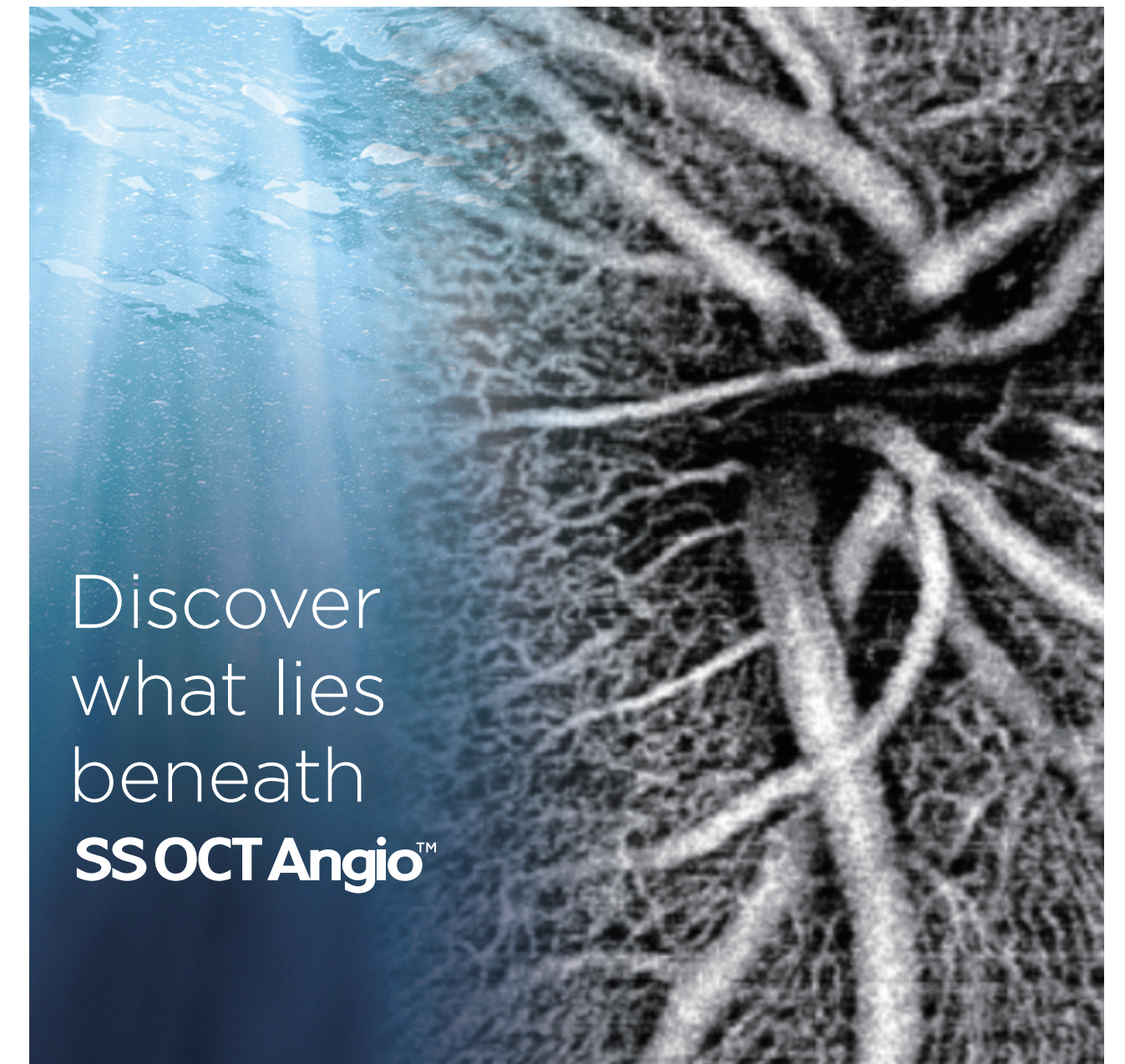

TOPCON CORPORATION

75-1 Hasunuma-cho, Itabashi-ku, Tokyo 174-8580, Japan.
Phone: 3-3558-2523/2522, Fax: 3-3960-4214, www.topcon.co.jp

OCT Angiography for Swept Source OCT

SS OCT Angio



Discover
what lies
beneath
SS OCT Angio™




Angio patient case: BRVO

Introducing SS OCT Angio™ with OCTARA™


DRI OCT Triton Series Swept Source Optical Coherence Tomography

OCT Angiography using Swept Source OCT superior imaging through a powerful combination of technologies

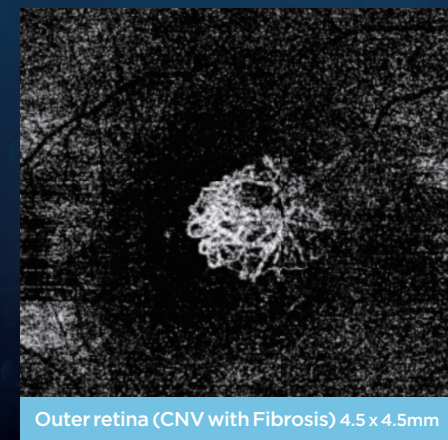
Topcon's SS OCT Angio™ is the only system that combines high-quality OCT angiography with a Swept Source OCT. Built on the clinically proven DRI OCT Triton platform, it is powered by OCTARA™, a proprietary image processing algorithm that provides highly sensitive angiographic detection. The exceptional visualization provides clear images of vascular structures, even in the choroid and deeper retinal layers*.




Superficial (AMD) 3.0 x 3.0mm



Deep (AMD) 3.0 x 3.0mm



Outer retina (CNV with Fibrosis) 4.5 x 4.5mm



Choroid (PCV) 6.0 x 6.0mm

Courtesy: Yusuke Ichiyama, MD Shiga University of Medical Science

Courtesy: Carl Glittenberg, MD, Karl Landsteiner Institute for Retinal Research and Imaging

High-sensitivity imaging and deeper intravascular flow visualization

Swept Source technology and OCTARA™ allow the deeper structures to be visualized with less depth-dependent signal roll-off, detecting even low microvascular flow with high-sensitivity. Additionally, the 1µm wavelength makes OCT imaging possible for patients with media opacities.

Rapid scanning, real time eye tracking

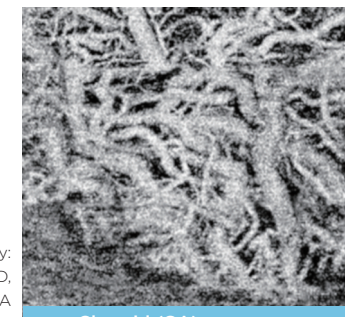
At 100,000 A scans per second, coupled with invisible scanning lines and the SMARTtrack eye tracking system, the 3D OCT Triton Swept Source OCT quickly completes the OCT Angiography* scan and provides a clear image of the retinal microvascular flow network.

* OCT Angiography scanning line may be faintly visible during capture to some people under certain conditions

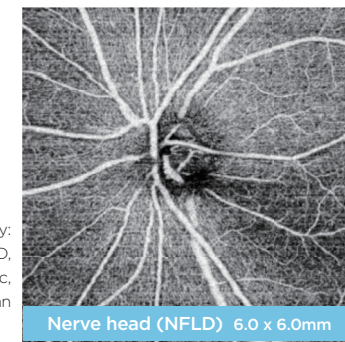
Enhanced diagnostic efficiency & workflow integration

Multimodal platform provides easy, yet comprehensive comparison of microvascular impairment with FA, FAF, OCT and color fundus images in a single device.*

*DRI OCT Triton plus



Courtesy: Srinivas R. Sadda, MD, Doheny Eye Institute, UCLA



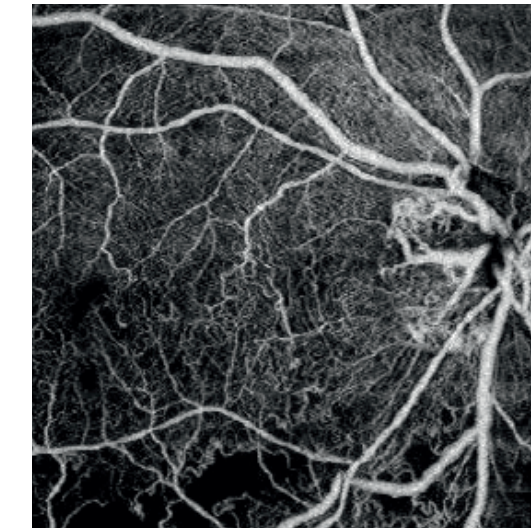
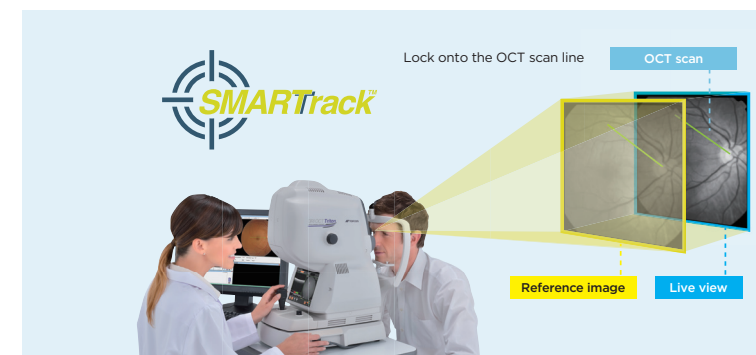Courtesy: Kazuya Yamagishi, MD, Hirakata Yamagishi Eye Clinic, Japan Scan

The OCTARA™ difference

OCTARA™ is the image processing technology which extracts the signal changes derived from vascular flow using multiple OCT B scans acquired at the same position. It demonstrates high-sensitivity for the detection of low blood flow in microvasculature. It is anticipated that OCTARA™ will be useful for detecting microaneurysms or capillary abnormalities.

Accurate tracking system

SMARTTrack™, incorporated in the DRI OCT Triton, has been further developed for OCT Angiography. It now detects eye movements and blinks instantaneously and modifies the scan position to ensure complete scanning of all areas.



BRVO

Physician: Carl Glittenberg MD, Karl Landsteiner Institute for Retinal Research and Imaging, Vienna, Austria

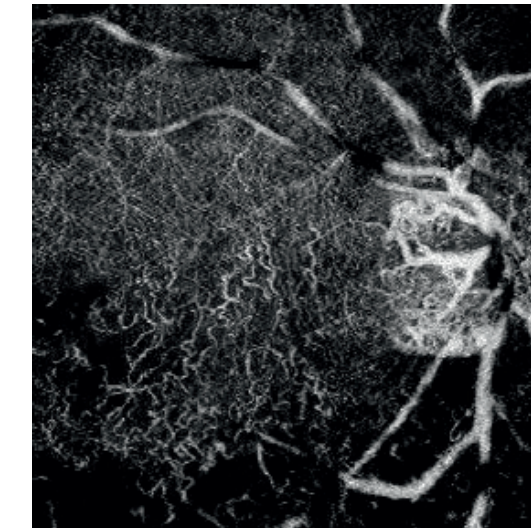
Patient history:

Gender: Male

Age: 64

Diagnosis: Branch retinal vein occlusion on the right eye

Treatment: Multiple intravitreal injections of anti-VEGF and laser treatment on the right eye.

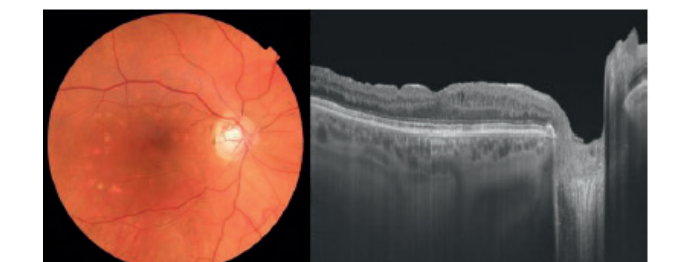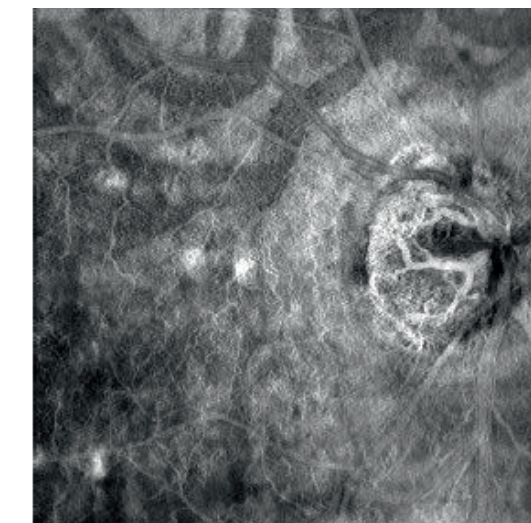


Examination techniques and results:

A high-definition swept source OCT B scan, a full color fundus photograph, and a swept source OCT angiography (SS OCT Angio™) were performed. The examinations were collected on a Topcon DRI OCT Triton™ Plus swept source OCT system. The fundus photograph shows vascular remodeling. The B scan shows residual cystoid macular edema. The SS OCT Angio™ shows marked retinal ischaemia inferior to the macula as well as vascular remodeling. OCT Angio images were post processed by Carl Glittenberg MD.

Clinical relevance:

The ability to have a quick and non-invasive method of screening patients for retinal ischaemia after retinal vein occlusion will make the treatment of these patients significantly more efficient.



* Reference: Pan-American association of ophthalmology 2015, Poster No. PP2219